

Diagnosis and Management of Infective Endocarditis and Its Complications

Arnold S. Bayer, MD; Ann F. Bolger, MD; Kathryn A. Taubert, PhD; Walter Wilson, MD; James Steckelberg, MD; Adolph W. Karchmer, MD; Matthew Levison, MD; Henry F. Chambers, MD; Adnan S. Dajani, MD; Michael H. Gewitz, MD; Jane W. Newburger, MD; Michael A. Gerber, MD; Stanford T. Shulman, MD; Thomas J. Pallasch, DDS, MS; Tommy W. Gage, RPh, DDS, PhD; Patricia Ferrieri, MD

From an Ad Hoc Writing Group of the Committee on Rheumatic Fever, Endocarditis, and Kawasaki Disease, American Heart Association

Infective endocarditis (IE) carries a high risk of morbidity and mortality. Rapid diagnosis, effective treatment, and prompt recognition of complications are essential to good patient outcome. Therapy of IE caused by the more commonly encountered organisms, including streptococci, enterococci, staphylococci, and the HACEK organisms (*Hemophilus parainfluenzae*, *Hemophilus aphrophilus*, *Actinobacillus [Hemophilus] actinomycetemcomitans*, *Cardiobacterium hominis*, *Eikenella* species, and *Kingella* species), has been addressed previously by this committee.¹ Likewise, the antimicrobial prevention of endocarditis has also been previously addressed.² In this article, we review and update the current literature with respect to diagnostic challenges and strategies, difficult therapeutic situations, and management choices in patients with IE. This article focuses predominantly on adults with IE. A separate article, currently in preparation, will address the issues of IE in childhood.

Diagnosis

Clinical Criteria

The diagnosis of IE is straightforward in those patients with classic oslerian manifestations: bacteremia or fungemia, evidence of active valvulitis, peripheral emboli, and immunologic vascular phenomena. In other patients, however, the classic peripheral stigmata may be few or absent.³ This may occur during acute courses of IE, particularly among intravenous drug abuse (IVDA) patients in whom IE is often due to

Staphylococcus aureus infection of right-sided heart valves, or in patients with IE caused by microorganisms such as HACEK. Acute IE evolves too quickly for the development of immunologic vascular phenomena, which are more characteristic of subacute IE. In addition, acute right-sided IE valve lesions do not create the peripheral emboli and immunologic vascular phenomena that can result from left-sided valvular involvement.³

The variability in the clinical presentation of IE requires a diagnostic strategy that will be both sensitive for disease detection and specific for its exclusion across all the forms of the disease. In 1981, von Reyn et al⁴ proposed a scheme for strict case definitions of IE (the Beth Israel criteria). These criteria were designed to be very stringent: cases were identified as “definite IE” only if pathological confirmation from surgical or autopsy specimen was available. “Probable IE” included patients with persistent bacteremia and evidence of either new valvular regurgitation or vascular phenomena in the face of underlying valvular heart disease. Several problems became apparent as these criteria were broadly applied to patients suspected of having IE. First, fewer than one third of IE patients require valvular surgery in the acute phase of their infection,⁵ and therefore only a minority of patients with bona fide IE could be classified as definite cases. Second, IVDA was not recognized as an important predisposing condition for the development of IE. Finally, echocardiographic findings were not included in the stratification strategy. As a result of these limitations, many IVDA patients with overt right-sided *S aureus* IE were rejected as definite cases, as were patients with blood culture–negative IE.

A more recent diagnostic strategy was proposed by Durack and colleagues from Duke University in 1994 (the Duke criteria).⁵ These Duke criteria (see Tables 1 and 2) combine the important diagnostic parameters contained in the Beth Israel criteria (persistent bacteremia, new regurgitant murmurs, and vascular complications) with echocardiographic findings. Moreover, IVDA is now recognized as an increasingly important underlying comorbid condition for development of IE. The Duke criteria stratify patients suspected of having IE into 3 categories: definite cases identified clinically (defined in Table 2) or pathologically (IE proven at surgery or autopsy), possible cases (not meeting the criteria for definite

This statement was approved by the American Heart Association Science Advisory and Coordinating Committee in September 1998. A single reprint is available by calling 800-242-8721 (US only) or writing the American Heart Association, Public Information, 7272 Greenville Ave, Dallas, TX 75231-4596. Ask for reprint No. 71-0155. To purchase additional reprints: up to 999 copies, call 800-611-6083 (US only) or fax 413-665-2671; 1000 or more copies, call 214-706-1466, fax 214-691-6342, or e-mail pubauth@amhrt.org. To make photocopies for personal or educational use, call the Copyright Clearance Center, 978-750-8400.

Correspondence to Kathryn A. Taubert, PhD, Senior Scientist, Department of Science and Medicine, American Heart Association, 7272 Greenville Ave, Dallas, TX 75231. E-mail ktaubert@heart.org (*Circulation*. 1998;98:2936-2948).

© 1998 American Heart Association, Inc.

Circulation is available at <http://www.circulationaha.org>

TABLE 1. Duke Clinical Criteria for Diagnosis of IE

| |
|---|
| Definite IE |
| Pathological criteria |
| Microorganisms: demonstrated by culture or histology in a vegetation, in a vegetation that has embolized, or in an intracardiac abscess, or |
| Pathological lesions: vegetation or intracardiac abscess present, confirmed by histology showing active endocarditis |
| Clinical criteria, using specific definitions listed in Table 2 |
| 2 major criteria, or |
| 1 major and 3 minor criteria, or |
| 5 minor criteria |
| Possible IE |
| Findings consistent with IE that fall short of "Definite" but not "Rejected" |
| Rejected |
| Firm alternate diagnosis for manifestations of endocarditis, or |
| Resolution of manifestations of endocarditis with antibiotic therapy for ≤ 4 days, or |
| No pathological evidence of IE at surgery or autopsy, after antibiotic therapy for ≤ 4 days |

Reprinted from Durack et al,⁵ *American Journal of Medicine*, with permission from Excerpta Medica Inc.

IE), and rejected cases (no pathological evidence of IE at autopsy or surgery, rapid resolution of the clinical syndrome with either no treatment or short-term antibiotic therapy, or a firm alternative diagnosis).

Major criteria in the Duke strategy include IE documented by data obtained at the time of open heart surgery or autopsy (pathologically definite) or via well-defined microbiological (blood culture) and echocardiographic data (clinically definite). To maintain the high specificity of blood culture results for IE, the Duke criteria require that some patients with bacteremia with common IE pathogens also fulfill secondary criteria. For example, bacteremia due to viridans streptococci and members of the HACEK group of fastidious Gram-negative rods, which are classic IE pathogens but rarely seen in patients without IE, are given primary diagnostic weight. In contrast, *S aureus* and *Enterococcus faecalis* commonly cause both IE and non-IE bacteremias. The Duke criteria, therefore, give diagnostic weight to bacteremia with staphylococci or enterococci only when they are community-acquired and without an apparent primary focus; these types of bacteremias have the highest risk of being associated with IE.⁶

The Duke criteria incorporate echocardiographic findings in the diagnostic strategy. Major diagnostic weight is given to only 3 typical echocardiographic findings: mobile, echodense masses attached to valvular leaflets or mural endocardium; periannular abscesses; or new dehiscence of a valvular prosthesis.

Six common but less-specific findings of IE are also included as minor criteria: intermittent bacteremia or fungemia, fever, major embolic events, nonembolic vascular phenomena, underlying valvular disease or IVDA, and echocardiographic abnormalities that fall short of typical valvular vegetations, abscesses, or dehiscence. Clinically definite IE by the Duke criteria requires the presence of 2 major criteria, 1 major criterion and 3 minor criteria, or 5 minor criteria

TABLE 2. Definitions of Terms Used in the Duke Criteria for the Diagnosis of IE

| |
|--|
| Major criteria |
| 1. Positive blood culture for IE |
| A. Typical microorganism consistent with IE from 2 separate blood cultures as noted below: |
| (i) viridans streptococci,* <i>Streptococcus bovis</i> , or HACEK group, or |
| (ii) community-acquired <i>Staphylococcus aureus</i> or enterococci, in the absence of a primary focus, or |
| B. Microorganisms consistent with IE from persistently positive blood cultures defined as |
| (i) ≥ 2 positive cultures of blood samples drawn >12 hours apart or |
| (ii) all of 3 or a majority of ≥ 4 separate cultures of blood (with first and last sample drawn ≥ 1 hour apart) |
| 2. Evidence of endocardial involvement |
| A. Positive echocardiogram for IE defined as |
| (i) oscillating intracardiac mass on valve or supporting structures, in the path of regurgitant jets, or on implanted material in the absence of an alternative anatomic explanation, or |
| (ii) abscess, or |
| (iii) new partial dehiscence of prosthetic valve, or |
| B. New valvular regurgitation (worsening or changing of preexisting murmur not sufficient) |
| Minor criteria |
| 1. Predisposition: predisposing heart condition or intravenous drug use |
| 2. Fever: temperature $\geq 38.0^{\circ}\text{C}$ |
| 3. Vascular phenomena: major arterial emboli, septic pulmonary infarcts, mycotic aneurysm, intracranial hemorrhage, conjunctival hemorrhages, and Janeway lesions |
| 4. Immunologic phenomena: glomerulonephritis, Osler's nodes, Roth spots, and rheumatoid factor |
| 5. Microbiological evidence: positive blood culture but does not meet a major criterion as noted above† or serological evidence of active infection with organism consistent with IE |
| 6. Echocardiographic findings: consistent with IE but do not meet a major criterion as noted above |

Reprinted from Durack et al,⁵ *American Journal of Medicine*, with permission from Excerpta Medica Inc.

*Includes nutritionally variant strains (*Abiotrophia* species).

†Excludes single positive cultures for coagulase-negative staphylococci and organisms that do not cause endocarditis.

(Table 1). Direct comparison of the Duke and Beth Israel criteria has been made in 11 major studies^{5,7-16} including nearly 1700 patients comprising geographically and clinically diverse groups (adult, pediatric, elderly [aged >60 years], patients from the community, those with and without IVDA, and patients with both native and prosthetic valves). These studies^{5,7-16} have confirmed the improved sensitivity of the Duke criteria and the diagnostic utility of echocardiography in identifying clinically definite cases (Table 3).

The calculated negative predictive value (number of true-negatives divided by number of true-negatives plus false-negatives) of the Duke criteria was $>98\%$ in a study in which 52 consecutive "IE rejected" patients were followed up for ≥ 3 months for a missed diagnosis of IE or late development of the infection.⁹ In another study, the specificity of rejecting

TABLE 3. Comparison of Duke Criteria With Beth Israel Criteria for the Clinical Diagnosis of IE: Summary of 11 Series^{5,7-16}

| Patients/Scheme | Clinically Definite | Probable | Possible | Rejected |
|---|---------------------|----------|----------|----------|
| Operated patients with surgically confirmed cases of endocarditis (n=286)* | | | | |
| Beth Israel | N/A | 47% | 29% | 24% |
| Duke | 74% | N/A | 26% | 0 |
| Nonoperated patients with clinically diagnosed cases of endocarditis (n=1395) | | | | |
| Beth Israel | N/A | 32% | 30% | 38% |
| Duke | 55% | N/A | 35% | 10% |

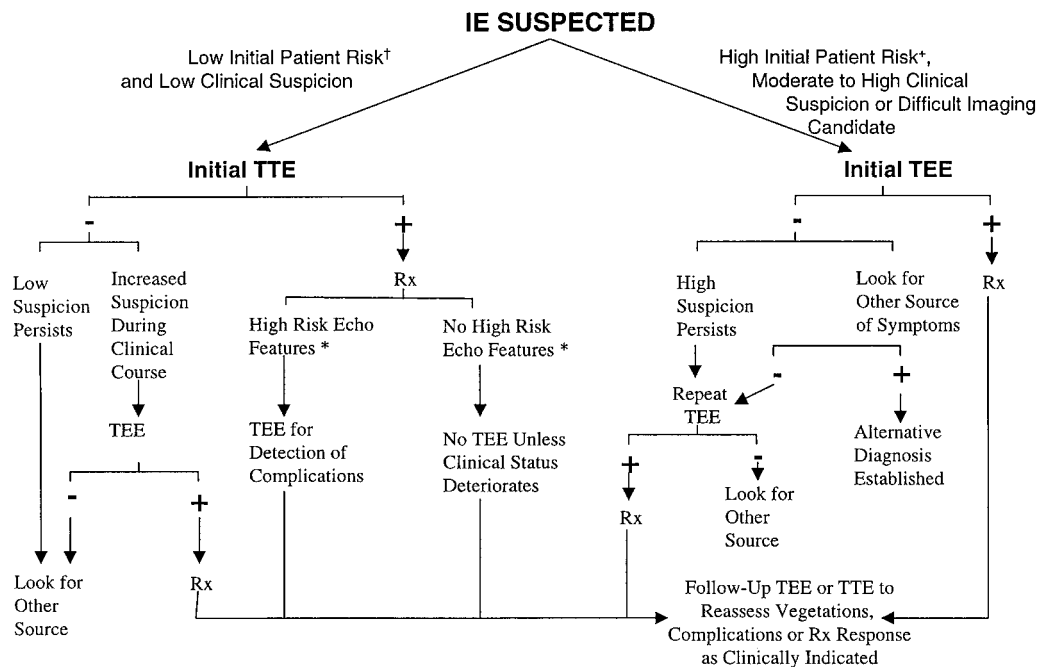
*Classified as if surgery had not been performed.

a case as IE by these criteria was evaluated in 100 patients with fever of unknown origin who had multiple blood cultures, as well as echocardiography, performed. Only 1 patient in whom a firm, alternative non-IE diagnosis had been established was reclassified as having clinically definite, blood culture-negative IE. This resulted in a specificity of 99% for the clinical diagnosis of IE by the Duke criteria.¹⁷ A retrospective study of 410 patients showed that the Duke criteria had good agreement (72% to 90%) with expert clinical assessment by infectious disease experts blinded to underlying IE risk factors.¹⁸

Several refinements in the Duke criteria are pending. Specific serological data may be included to more precisely establish the diagnoses of “culture-negative” endocarditis. Such serological criteria would be applied in circumstances in which the etiologic organism is either slow growing or requires special culture media (eg, *Brucella*) or in which the organism is not readily cultivated in most clinical microbiology laboratories (eg, *Coxiella burnetii*, *Bartonella quin-*

*tana*¹⁹). Expansion of “minor criteria” to include elevated erythrocyte sedimentation rate or C-reactive protein, the presence of newly diagnosed clubbing, splenomegaly, and microscopic hematuria has been proposed.²⁰ In a study of 100 consecutive cases of pathologically proven native-valve IE, inclusion of these additional parameters with the existing Duke minor criteria resulted in a 10% increase in the frequency of cases being deemed clinically definite, with no loss of specificity. Finally, adjustment of the Duke criteria to require a minimum of 1 major criterion or 3 minor criteria to designate a case as “possible IE” would reduce the proportion of patients assigned to that category.²¹

Thus, on the basis of the weight of clinical evidence involving nearly 1700 patients in the current literature, it would appear that patients suspected of having IE should be clinically evaluated, with the Duke criteria used as the primary diagnostic schema. It is hoped that the proposed modifications to the Duke criteria outlined above will provide even more sensitivity and specificity to this schema.



An approach to the diagnostic use of echocardiography (echo). *High-risk echocardiographic features include large and/or mobile vegetations, valvular insufficiency, suggestion of perivalvular extension, or secondary ventricular dysfunction (see text). †For example, a patient with fever and a previously known heart murmur and no other stigmata of IE. +High initial patient risks include prosthetic heart valves, many congenital heart diseases, previous endocarditis, new murmur, heart failure, or other stigmata of endocarditis. Rx indicates antibiotic treatment for endocarditis.

TABLE 4. Clinical Situations Constituting High Risk for Complications for IE

| |
|---|
| Prosthetic cardiac valves |
| Left-sided IE |
| <i>S aureus</i> IE |
| Fungal IE |
| Previous IE |
| Prolonged clinical symptoms (≥ 3 months) |
| Cyanotic congenital heart disease |
| Patients with systemic to pulmonary shunts |
| Poor clinical response to antimicrobial therapy |

Echocardiography

Echocardiography plays an important role in the diagnosis and management of IE. Characteristic vegetations, abscesses, new prosthetic-valve dehiscence, or new regurgitation are 4 powerful identifiers of IE in combination with other clinical parameters.⁵ Echocardiography is not an appropriate screening test in the evaluation of patients with fever or a positive blood culture that is unlikely to reflect IE. Nevertheless, some form of echocardiography should be performed in all patients suspected of having IE (Figure). Transthoracic echocardiography (TTE) is rapid, noninvasive, and has excellent specificity for vegetations (98%).²² The overall sensitivity for vegetations, however, is $< 60\%$.²²⁻²⁴ Vegetations > 2 mm in diameter,²⁵ particularly those on the right-sided valves (which lie closer to the chest wall), are readily detected by TTE. TTE views may be inadequate in up to 20% of adult patients because of obesity, chronic obstructive pulmonary disease, or chest-wall deformities. In patients suspected of having IE, TTE alone cannot exclude several important aspects of IE, including infection on prosthetic valves, periannular abscess, leaflet perforation, and fistulae.^{24,26}

In patients in whom IE or its complications are strongly suspected (Table 4) (for example, patients with prosthetic valves, community-acquired staphylococcal bacteremia, or new atrioventricular block), a negative TTE of even the highest quality will not definitely rule out IE. Moreover, a positive TTE in such patients may demonstrate vegetations but will not suffice to rule out the important complications. In patients with a relatively low risk for IE (for example, bacteremia due to enterococci in patients with an obvious primary focus and without other stigmata of IE), a good-quality negative TTE is generally adequate to rule out IE. Subsequent transesophageal echocardiography (TEE) can be performed if the clinical picture changes, if there is no improvement with therapy, or if complications are suspected.²²

TEE is safe in experienced hands²⁷ and has a sensitivity for detection of vegetations in IE that is very high. TEE images benefit from higher ultrasonic frequencies, which improve spatial resolution and the elimination of interference from interposed tissues. TEE has a substantially higher sensitivity (76% to 100%) and specificity (94%) than TTE for perivalvular extension of infection²⁸⁻³⁰ because the TEE transducer in the esophagus is in physical proximity to the aortic root and basal septum, where most such complications occur. TEE

also enhances visualization of prosthetic valves, with 86% to 94% sensitivity and 88% to 100% specificity for IE vegetations.^{26,29-31} Also, prosthetic valvular insufficiency is much better defined on TEE, in which valve structures do not interfere with the Doppler signal.³² The sensitivity of TEE can be further improved by imaging in ≥ 2 planes, because incremental planes decrease the number of false-negative studies and improve the definition of vegetation extent and mobility.²⁸ The excellent performance of TEE makes it the method of choice in the diagnosis of IE in patients who are difficult to image, in possible prosthetic-valve IE, in patients with intermediate or high clinical suspicion of IE, and in those patients with a high risk for IE-related complications (Table 4). One recently published study comparing TTE and TEE in patients with *S aureus* bacteremia (SAB) found TEE was essential to establish a diagnosis of IE and to detect associated complications.³³ The authors concluded that TEE "should be considered part of the early evaluation of patients with SAB." TEE, like other forms of gastrointestinal endoscopy, does not require antibiotic prophylaxis,² although the physician may choose to administer prophylaxis to patients with high-risk underlying cardiac conditions (eg, prosthetic heart valves) and poor dental health.

Clinical suspicion of IE may persist after an initially negative TEE. A negative TEE does not have enough diagnostic accuracy to rule out vegetative IE.²² Potential sources of false-negative TEE studies include vegetations that are smaller than the limits of resolution, previous embolization of vegetation, or inadequate views to detect small abscesses.³ Accurate differentiation between true vegetations and other IE-related changes, such as ruptured chordae, is frequently difficult.²³ It is also important to emphasize that there are blind spots with TEE. For example, the same prosthetic shadows that interfere with TTE views may obstruct structural visualization by TEE. Multiple TEE planes combined with TTE views must be exploited to minimize the risk of missing a significant finding when images are technically difficult to obtain. When both TEE and TTE studies are negative, there is a 95% negative predictive value.^{3,34} When clinical suspicion of IE is high and the TEE results are negative, a repeat TEE study is warranted within 7 to 10 days, which may demonstrate previously undetected vegetations or abscesses. Follow-up echocardiographic studies at the completion of therapy demonstrate persistent vegetations in 59% of cases; in the absence of severe valvular regurgitation or ongoing clinical symptoms, such persistence does not correlate with late complications.³⁵ In contrast, increase in vegetation size by echocardiography over the course of therapy may identify a subset of patients with a higher rate of complications, independently of the presence of persistent bacteremia or overt clinical stigmata of IE.³⁶

Approach to the Patient With Apparent Blood Culture-Negative IE

Positive blood cultures are a major diagnostic criterion for IE and are key in identifying the etiologic agent and its antimicrobial susceptibility.^{37,38} Continuous bacteremia and a high frequency of positive blood cultures are typical of this infection. In a study of 206 patients with blood culture-

positive IE, 95% of 789 blood cultures yielded the causative microorganism, and all the cultures were positive in 91% of cases.³⁹ However, the intensity of the bacteremia may not be great; fewer than 50 colony-forming units per milliliter of blood were detected in the majority of patients.³⁹

Blood cultures are negative in $\leq 5\%$ of patients with IE diagnosed by strict diagnostic criteria.^{40,41} Failure to culture the organism in IE may result from inadequate microbiological techniques, infection with highly fastidious bacteria or nonbacterial microorganisms, or most importantly, from the administration of antimicrobial agents before blood cultures are obtained. Blood from patients suspected of having IE should be cultured in 3 sets (each set equals 1 aerobic plus 1 anaerobic bottle). The blood should be diluted at least 1:5 into the broth media, and the laboratory should be advised that the clinical diagnosis is IE. When all blood cultures remain negative after 48 to 72 hours, the microbiology laboratory should incubate these cultures for a more prolonged period (at least 2 to 3 weeks), microscopically examine an acridine orange–stained aliquot from all bottles (even in the absence of detectable growth), and on day 7, day 14, and at the end of the incubation period, blindly subculture an aliquot on chocolate agar for further incubation (3 to 4 weeks) in an atmosphere of increased carbon dioxide (candle jar). These steps may facilitate recovery of fastidious bacteria.

The administration of antimicrobial agents to patients with IE before blood cultures are obtained reduces the recovery rate of bacteria by 35% to 40%.^{38–40,42,43} The antimicrobial susceptibility of the organism and the duration and nature of prior antimicrobial therapy together determine the length of time that blood cultures will remain negative.⁴¹ IE patients with initially negative blood cultures after only a few days of antibiotic therapy may have positive blood cultures after several days without antibiotics. The blood cultures of patients who received longer courses of high-dose bactericidal antimicrobials may remain negative for weeks. Among patients with a clinical syndrome consistent with IE who have recently received antibiotics, empiric antimicrobial therapy should be delayed if they do not have a toxic appearance and have no clinical or echocardiographic evidence of severe or progressive valve regurgitation or of congestive heart failure (CHF). If the initial blood cultures are negative, a delay of 2 to 4 days will allow additional blood cultures to be obtained without the confounding effect of further antibiotic therapy and without increased morbidity from IE. Special efforts to neutralize or inactivate antimicrobial agents present in blood, such as the addition of penicillinase, have not been shown to substantially enhance the yield of blood cultures in IE and are not routinely recommended.^{38,41} However, in most large hospitals, automated blood culture detection systems are used that are highly sensitive, and these systems frequently use blood-collection vials with antibiotic binding resins.

Some IE pathogens are difficult to isolate from blood cultures. To recover the HACEK organisms, prolonged incubation and subcultures as noted above may be required. *Bartonella* species, recently recognized as an important cause of apparent culture-negative IE, can also be isolated by prolonged incubation and subculture of the aerobic broth media^{44–49}; subculture on endothelial cell tissue culture may

be required in some instances.⁴⁸ The nutritionally variant streptococci (now classified as *Abiotrophia* species) account for $\approx 5\%$ to 7% of streptococcal IE cases. These strains frequently fail to grow when the blood cultures are subcultured onto standard blood agar media. These organisms can be grown on blood agar as satellite colonies around an *S aureus* streak or when the agar media is supplemented with L-cysteine or pyridoxal hydrochloride.^{38,41} Isolation of *Brucella* species is facilitated by the prolonged incubation of cultured blood in Castañeda bottles containing biphasic soybean casein–digest medium, with a carbon dioxide–enriched atmosphere, but they may also grow in media used for the automated blood culture detection systems. *Legionella* species, a rare cause of prosthetic-valve IE, can be isolated from blood by subculture of aerobic blood culture bottles or lysis-concentration pellets on buffered charcoal yeast extract agar.⁵⁰ Some fungi that cause IE are almost never recovered from blood (eg, *Aspergillus* species), whereas others are isolated in sporadic blood cultures. The frequency of isolation for these latter fungi (eg, *Candida* species, *Cryptococcus neoformans*, and other yeasts) is increased with the use of the lysis-centrifugation technique or Castañeda bottles.^{38,42} These yeasts will also grow in media used in the automated instruments.

Coxiella burnetii (the agent of Q fever) has not been recoverable from blood cultures until recently. Although this organism has now been recovered from the blood of patients with IE by tissue-culture–based techniques,^{51–53} infection with this agent is far more likely to be identified by serological tests. High titers of antibody directed against the phase I antigen (IgG titers $>1:400$ by complement fixation or $\geq 1:800$ by microimmunofluorescence, or IgA titer $\geq 1:100$) in blood culture–negative patients with echocardiographic evidence of IE is diagnostic in Q-fever IE.^{51,53} The presumptive diagnosis of *Brucella*, *Bartonella*, or chlamydial endocarditis can also be made serologically.^{49,52}

In addition to blood cultures and serological assays, culture of valve tissue or vegetations that have embolized to peripheral arteries and have been removed surgically may reveal the causative organism. Specific light-microscopy fluorescent-labeled antibody stains, electron microscopy, or molecular techniques to recover specific DNA or 16S rRNA from blood or tissue samples may also assist in diagnosis.^{48,54–56} Polymerase chain reaction performed on blood may be useful for diagnosis of endocarditis caused by *Tropheryma whipplei* or *Bartonella* species. As experience with this technique in patients with IE grows, polymerase chain reaction may prove useful for the diagnosis of infection caused by other microorganisms.

Management

Therapy of Unusually Encountered Organisms

Coagulase-Negative Staphylococci

Although coagulase-negative staphylococci (CNS) are the most common cause of prosthetic-valve IE,⁵⁷ until recently they had been infrequently associated with native-valve IE. However, over the past decade, there have been a number of reports documenting the occurrence of native-valve CNS

IE.⁵⁸⁻⁶⁰ Most of the reported patients had documented underlying valvular abnormalities, particularly mitral valve prolapse. The clinical course of these patients is typically indolent, with good responses to medical or surgical therapy (see Reference 1 for discussion of antimicrobial therapy). An important subset of patients with CNS IE has been identified recently: those with infection caused by *Staphylococcus lugdunensis*. This CNS organism tends to cause a substantially more virulent form of IE than other CNS, with high rates of perivalvular extension of infection and metastatic seeding to distant organs, despite uniform susceptibility in vitro to most antibiotics.⁶¹⁻⁶³ Most experts recommend that IE caused by this organism be treated with standard regimens based on the in vitro susceptibility profiles of the strain and that the patient be monitored carefully for development of periannular extension or extracardiac spread of infection. The differentiation of *S. lugdunensis* from other CNS may be difficult in the microbiology laboratory with routine commercial identification schema and may require referral to a reference laboratory.⁶⁴

Coxiella burnetii

Coxiella burnetii possesses a Gram-negative-like cell wall and is a strict intracellular pathogen that grows in the acidic phagolysosome of the host cell. Q fever is a relatively common cause of IE in geographic areas of the world in which cattle, sheep, and goat farming are common. The organism is resistant to desiccation; inhalation of aerosols of contaminated soil is the major mode of transmission, although ingestion of infected unpasteurized milk may also transmit the disease. Q-fever IE usually affects prosthetic or previously damaged aortic or mitral valves.⁶⁵ The small vegetations from this predominantly subendothelial infection are often missed by echocardiography.⁶⁵ The optimal regimen or duration of antimicrobial therapy for Q-fever IE is unknown. Doxycycline with trimethoprim/sulfamethoxazole, rifampin, or fluoroquinolones is the mainstay of therapy.⁶⁶ However, eradication of the organisms from vegetations with medical therapy is unlikely, and reinfection of prosthetic material after surgical replacement of infected valves commonly occurs. The acidic conditions of the phagolysosome, where the organism resides, may inhibit antibiotic activity.⁶⁶ Clinical response tends to persist as long as the drug regimen continues, but viable *C. burnetii* can be recovered from valve tissue even after years of antimicrobial therapy.⁶⁶ Cures of IE after treatment with a combination of doxycycline and hydroxychloroquine (to alkalinize the phagolysosome) for 1 year were reported in 20 patients.⁶⁵ However, no long-term follow-up was published regarding these patients. After completion of antimicrobial therapy for Q fever, relapse may occur early or after a prolonged period of time. Accordingly, more data are necessary to clarify the efficacy of doxycycline-hydroxychloroquine therapy for Q-fever endocarditis. Valve replacement is indicated only for CHF, prosthetic-valve involvement, or uncontrolled infection.⁶⁵ To prevent reinfection of the newly implanted prosthetic valve from dormant sites of infection, many experts recommend that antimicrobial therapy be continued long-term and possibly indefinitely.⁶⁶ Some authorities have suggested a mini-

mum of 3 years' therapy once phase I IgG antibody titers drop below 1:400 and IgA phase I antibodies are undetectable.^{65,66}

Brucellae

Brucellae are facultative intracellular Gram-negative bacilli that infect humans after ingestion of infected undercooked meat or unpasteurized milk, inhalation of infectious aerosols, or direct contact with infected tissues. Brucellosis is an occupational disease of veterinarians, abattoir workers, livestock handlers, and shepherds; it causes ≈4% of all IE cases in Spain.⁶⁷ Previously damaged aortic or mitral valves develop bulky vegetations, followed commonly by valve destruction, perivalvular abscesses, and CHF. Few patients with *Brucella* IE have been cured with antimicrobial agents alone.⁶⁸ Most require valve replacement in combination with antimicrobial agents. The optimal regimen or duration of antimicrobial therapy for *Brucella* endocarditis is unknown: doxycycline plus either streptomycin or gentamicin or doxycycline plus trimethoprim/sulfamethoxazole or rifampin have been recommended by some authorities for ≥8 weeks and up to 10 months after valve replacement.^{67,69}

Candida and Aspergillus

Candida and *Aspergillus* species cause the majority of fungal IE. Intravenous drug abusers, prosthetic-valve recipients, and patients with long-term central venous catheters are at highest risk for IE, which should be suspected in the presence of negative blood cultures, bulky vegetations, metastatic infection, perivalvular invasion, or embolization to large blood vessels.⁷⁰ Amphotericin B, the only fungicidal agent available, has poor penetration into vegetations; cure usually requires valve surgery in addition to amphotericin B.^{68,70-72} Although the imidazoles (eg, fluconazole or itraconazole) have no proven efficacy in human fungal IE, a number of case reports (particularly in adults who are not valve-replacement candidates) suggest that long-term suppressive therapy with these agents may be effective.^{70,73}

Legionella

All cases of *Legionella* IE have had a febrile course that extended over months, with cardiac signs of newly developed murmurs and extremely high anti-*Legionella* antibody titers. Most patients have had prosthetic cardiac valves.^{50,74,75} Blood cultures, which are usually sterile on routine media, will grow the organism when special media are used.⁵⁰ Annular abscess and small vegetations have been visible at surgery, although echocardiograms have been negative. Embolic events are unusual, in contrast to their frequency with other culture-negative endocarditis, such as Q fever and fungal endocarditis.

Cure has been obtained in patients by prolonged parenteral antimicrobial therapy with either doxycycline or erythromycin, followed by prolonged oral therapy with these agents.⁵⁰ Response to therapy has been associated with a falling antibody titer. The total duration of therapy has usually been 6 to 17 months. Most patients have additionally required valve replacement because of valvular incompetence but not necessarily for persistent infection or embolic events.

Pseudomonas

Most cases of *Pseudomonas* IE are caused by *P aeruginosa* and occur in the setting of IVDA.^{76,77} Isolated right-sided pseudomonas IE can generally be managed with antibiotic therapy, with or without valve surgery.⁷⁸ Large doses of an antipseudomonal penicillin (eg, piperacillin 18 g/d) combined with an aminoglycoside (eg, tobramycin 5 to 8 mg · kg⁻¹ · d⁻¹) are the usual treatment.^{77,79} However, medical therapy alone has rarely been effective in left-sided disease; valve replacement is considered mandatory for cure of left-sided pseudomonas IE.^{76,77}

Congestive Heart Failure

Among the complications of IE, CHF has the greatest impact on prognosis.⁸⁰ In native-valve IE, acute CHF occurs more frequently in aortic-valve infections (29%) than with mitral (20%) or tricuspid disease (8%).⁸¹ CHF may develop acutely from perforation of a native- or bioprosthetic-valve leaflet, rupture of infected mitral chordae, valve obstruction from bulky vegetations, or sudden intracardiac shunts from fistulous tracts or prosthetic dehiscence.

CHF may also develop more insidiously, despite appropriate antibiotics, as a result of a progressive worsening of valvular insufficiency and ventricular dysfunction. Patients who have normal ventricular function or only mild CHF at initial diagnosis of IE may progress to severe CHF during treatment, and two thirds of those patients will do so within the first month of therapy.⁸¹ CHF in IE, irrespective of the course or mechanism, portends a grave prognosis with medical therapy alone and is also the most powerful predictor of poor outcome with surgical therapy.⁸² Delaying surgery to the point of frank ventricular decompensation dramatically increases operative mortality, from 6% to 11% for patients without CHF and 17% to 33% for patients with CHF.^{83,84}

Echocardiographic evaluation of IE patients delineates the causes and severity of CHF. Ventricular size, wall motion, and dynamic function can be readily defined and valve insufficiency quantified. Progressive chamber enlargement, elevation of pulmonary arterial pressures, and increasing wall stress on serial evaluation all indicate a trend toward decompensation. Medical and surgical management decisions can be guided by echocardiographic detection of abscesses, fistulae, prosthetic dehiscence, obstructive vegetations, or flail leaflets, none of which will resolve with medical therapy alone. Table 5 lists the echocardiographic features that suggest potential need for surgical intervention.

The decision to operate on the patient with IE is driven primarily by the severity of CHF. Poor surgical outcome is predicted by preoperative New York Heart Association class III or IV CHF, renal insufficiency, and advanced age. In any patient, a decision to delay surgery to extend preoperative antibiotic treatment carries with it the risk of permanent ventricular dysfunction. The incidence of reinfection of newly implanted valves in patients with active IE has been estimated to be 2% to 3%,^{85,86} far less than the mortality rate for uncontrolled CHF.

Surgical approaches to IE patients with CHF must be tailored to the distortion of the valve and its surrounding structures. Severe valvular disruption will require prosthetic

TABLE 5. Echocardiographic Features Suggesting Potential Need for Surgical Intervention*

| |
|---|
| Vegetation |
| Persistent vegetation after systemic embolization: |
| Anterior mitral leaflet vegetation, particularly with size >10 mm† |
| One or more embolic events during first 2 weeks of antimicrobial therapy† |
| Two or more embolic events during or after antimicrobial therapy† |
| Increase in vegetation size after 4 weeks of antimicrobial therapy†‡ |
| Valvular dysfunction |
| Acute aortic or mitral insufficiency with signs of ventricular failure‡ |
| Heart failure unresponsive to medical therapy‡ |
| Valve perforation or rupture‡ |
| Perivalvular extension |
| Valvular dehiscence, rupture, or fistula‡ |
| New heart block‡ |
| Large abscess, or extension of abscess despite appropriate antimicrobial therapy‡ |

*See text for more complete discussion of indications for surgery based on vegetation characterizations.

†Surgery may be required because of risk of embolization.

‡Surgery may be required because of heart failure or failure of medical therapy.

replacement, although in some cases successful valve-repair procedures, as an alternative to valve replacement, have been reported.^{87,88} Ruptured mitral chordae may sometimes be repaired with a combination of leaflet resection, chordal reattachment or transposition, and annular support. Leaflet perforations may be repairable with small pericardial patches if the surrounding leaflet tissue is well-preserved and valve motion can be maintained. Similarly, in selected cases, discrete vegetations on aortic or mitral leaflets have been excised along with underlying leaflet tissue and repaired with a patch. Experience with vegetation excision has been limited to date.

Risk of Embolization

Systemic embolization occurs in 22% to 50% of cases of IE.^{25,80,89,90} Emboli often involve major arterial beds, including lungs, coronary arteries, spleen, bowel, and extremities. Up to 65% of embolic events involve the central nervous system, and >90% of central nervous system emboli lodge in the distribution of the middle cerebral artery. These latter emboli are associated with a high mortality rate.⁹¹ The highest incidence of embolic complications is seen with aortic- and mitral-valve infections and in IE due to *S aureus* and *Candida* species and HACEK and *Abiotrophia* organisms. Emboli can occur before diagnosis, during therapy, or after therapy is completed, although most emboli occur within the first 2 to 4 weeks of antimicrobial therapy.⁹² Of note, the rate of embolic events drops dramatically during the first 2 weeks of successful antibiotic therapy, from 13 to <1.2 embolic events per 1000 patient-days.⁹³

Prediction of individual patient risk for embolization has proven extremely difficult. Many studies have attempted to use echocardiography to identify a high-risk subset of IE

patients who might benefit from early surgery to avoid embolization. Several studies using TTE have demonstrated a trend toward higher embolic rates with left-sided vegetations that are >1 cm in diameter.⁹⁴ In a study based on TEE, mitral vegetations >1 cm in diameter were associated with the greatest incidence of embolism. The association was strengthened when analysis was limited to those patients who had not yet experienced a clinical embolic event. Among such patients, the predictive accuracy for embolism with large mitral vegetations was nearly 100%.²³ Another prospective TEE study, however, found no clear correlation of vegetation size with embolization.⁹⁵ Overall, these data are compatible with previous observations that in general, mitral vegetations, regardless of size, are associated with higher rates of embolization (25%) than aortic vegetations (10%). Of interest, the highest embolic rate (37%) has been seen in the subset of patients with mitral vegetations attached to the anterior rather than the posterior mitral leaflet.^{36,96} This implies that the mechanical effects of broad and abrupt leaflet excursion, occurring twice per heartbeat, may contribute to the propensity of a vegetation to fragment and embolize.

In another study, the effect of vegetation size on embolic potential was specific to the infecting organism, with large vegetations independently predicting embolic events only in the setting of streptococcal IE.⁹³ In contrast, staphylococcal or fungal IE appears to carry a high risk of embolization that is independent of vegetation size. The number of vegetations, the number of valves involved, and vegetation characteristics (eg, lack of calcification) predicted embolic complications in one study.⁹⁵ Vegetation mobility has not been shown to be an independent risk factor for embolic events, probably because it is strongly correlated with vegetation size.²³

Embolic events do appear to be predicted by an increase in vegetation size by TEE over 4 to 8 weeks of therapy. The embolic event rate among patients with IE and increasing vegetation size was twice that of patients with static or decreasing vegetation size. In addition, a second peak of late embolic events occurred at 15 to 30 weeks after diagnosis of IE and was associated with nonhealing vegetations (failure of a vegetation to stabilize or diminish in size) as defined by echocardiography.³⁶

The traditional indications for valvular surgery in IE to avoid embolization have been ≥ 2 major embolic events.⁹⁷ These criteria are arbitrary and exclude cutaneous embolization, which is common, or embolism occurring before the institution of therapy.⁹⁸ Because of the known decrease in embolic risk over the first 2 weeks of antibiotic therapy, the benefit of surgery in avoiding catastrophic embolic events is greatest early in the course of the IE. Early surgical intervention may preclude a primary or recurrent major embolic event but exposes the patient to both the immediate and the life-long risks of valve replacement. At this time, the strategy for surgical intervention to avoid systemic embolization in IE remains specific to the individual patient, with benefit being greatest in the early phase of IE when embolic rates are highest and when other predictors of a complicated course (ie, recurrent embolization; CHF; aggressive, antibiotic-resistant organisms; or prosthetic-valve IE) are present (Table 5). Surgical options must be considered when large vegetations

are detected on the mitral valve, particularly the anterior leaflet. Failure of a vegetation to stabilize or diminish in size on TEE during clinically adequate therapy may also predict later embolic events.

Periannular Extension of Infection

Extension of IE beyond the valve annulus predicts higher mortality, more frequent development of CHF, and the need for cardiac surgery.^{96,99,100} Perivalvular cavities form when annular infections break through and spread into contiguous tissue. In native aortic-valve IE, this generally occurs through the weakest portion of the annulus, which is near the membranous septum and atrioventricular node.¹⁰¹ The anatomic vulnerability of this area explains both why abscesses occur in this location and why heart block is a frequent sequela.^{28,102} Periannular extension is common, occurring in 10% to 40% of all native-valve IE, and complicates aortic IE more commonly than mitral or tricuspid IE.^{82,103,104} Periannular infection is of even greater concern with prosthetic-valve IE, occurring in 56% to 100% of patients.¹⁰² Perivalvular abscesses are particularly common with prosthetic valves because the annulus, rather than the leaflet, is the usual primary site of infection.^{57,105} Most periannular infections involving the mitral area are associated with prosthetic mitral valves.

Under the influence of systemic intravascular pressures, abscesses may progress to fistulous tracts that create intracardiac or pericardial shunts. In some cases, progressive periannular infection totally disrupts the ventricular-aortic continuity or the mitral-aortic trigone. Such structural lesions and intracardiac fistulas may be catastrophic; even if their hemodynamic impact is tolerated, such lesions will not heal with medical management alone, and they require urgent operative intervention.

Clinical parameters for the diagnosis of perivalvular extension of IE are inadequate. Persistent bacteremia or fever, recurrent emboli, heart block, CHF, or a new pathological murmur in a patient with IE who is taking adequate antibiotics may suggest extension.^{28,106} Only aortic-valve involvement and recent IVDA have been prospectively identified as independent risk factors for perivalvular abscess.¹⁰⁰ On ECG, new atrioventricular block has an 88% positive predictive value (number of true-positives divided by number of true-positives plus false-positives) for abscess formation but has a low sensitivity (45%).¹⁰²

Patients at risk for perivalvular extension of IE require prompt evaluation. The size of vegetations is not helpful in predicting perivalvular extension.¹⁰⁰ The sensitivity of TTE to detect perivalvular abscess is low (18% to 63% in prospective and retrospective studies, respectively).^{95,107,108} TEE dramatically improves the sensitivity for defining periannular extension of IE (76% to 100%) while retaining excellent specificity (95%) and positive and negative predictive values (87% and 89%, respectively).^{28,30,95} When it is combined with spectral and color Doppler techniques, TEE can demonstrate the distinctive flow patterns of fistulae and pseudoaneurysms and can rule out communications from unruptured abscess cavities. Because of these combined capabilities, TEE is the

modality of choice for initial assessment of any patient at risk for perivalvular extension of IE.^{29,30}

A small number of patients with periannular extension of infection or myocardial abscess may be treated successfully without surgical intervention.^{109,110} These patients include those who do not have heart block, echocardiographic evidence of progression of abscess during therapy, valvular dehiscence, or insufficiency. Such patients should be monitored closely with serial TEE, and TEE should be repeated at intervals of 2, 4, and 8 weeks after completion of antimicrobial therapy.

Surgery for patients with perivalvular extension of IE is directed toward eradication of the infection as well as correction of hemodynamic abnormalities. Drainage of abscess cavities, excision of necrotic tissue, and closure of fistulous tracts often accompanies valve-replacement surgery.¹¹¹ Although valve replacement is usually required, this may be complicated in the face of extensive destruction of the periannular supporting tissues. In these conditions, human aortic homografts, when available, can be used to replace the damaged aortic valve as well as to reconstruct the damaged aorta.^{112,113} Homografts have a constant but low risk for the development of sewing-ring infections and IE, possibly related to improved penetration of antibiotics.¹¹⁴

Splenic Abscess

Splenic abscess is a well-described but rare complication of IE. This infection develops via 1 of 2 mechanisms: bacteremic seeding of a bland infarction, created via splenic artery occlusion by embolized vegetations, or direct seeding of the spleen by an infected embolus also originating from an infected valvular vegetation. Although splenic infarction is a common complication of left-sided IE ($\approx 40\%$ of cases), it is estimated that only $\approx 5\%$ of patients with splenic infarction will develop splenic abscess.^{115–117} Viridans streptococci and *S aureus* each account for $\approx 40\%$ of cases in which splenic abscess cultures are positive, whereas the enterococci account for $\approx 15\%$ of cases. Aerobic Gram-negative bacilli and fungi are isolated in $< 5\%$ of cases. Clinical splenomegaly, present in up to 30% of cases of IE, is not a reliable sign of splenic infarction or abscess. Splenic infarction delineated by imaging techniques is often asymptomatic¹¹⁷; back, left-flank, or left-upper-quadrant pain or abdominal tenderness, when present, may be associated with either splenic infarction or abscess.^{115,117–120} Splenic rupture with hemorrhage is a rare complication of infarction. Persistent or recurrent bacteremia, persistent fever, or other signs of sepsis are suggestive of splenic abscess, and patients with these findings should be evaluated with ≥ 1 of the imaging studies discussed below.

Abdominal CT or MRI appear to be the best tests for diagnosis of splenic abscess, with sensitivities and specificities of $\approx 90\%$ to 95%. By CT, splenic abscess is frequently seen as single or multiple contrast-enhancing cystic lesions, whereas infarcts typically are peripheral low-density, wedge-shaped areas. On ultrasonography, a sonolucent lesion suggests abscess. ^{99m}Tc liver-spleen scans, labeled white blood cell scans, and gallium scans have become obsolete for the diagnosis of splenic abscess.

Differentiation of splenic abscess from bland infarction may be difficult. Infarcts are generally associated with clinical and radiographic improvement during appropriate antibiotic therapy. Ongoing sepsis, recurrent positive blood cultures, and persistence or enlargement of splenic defects on CT or MRI suggest splenic abscess, which responds poorly to antibiotic therapy alone. Definitive treatment is splenectomy with appropriate antibiotics, and this should be performed immediately, unless urgent valve surgery is planned. Percutaneous drainage or aspiration of splenic abscess has been performed successfully,^{121,122} and this procedure may be an alternative to splenectomy for the patient who is a poor surgical candidate. Splenectomy should be performed before valve-replacement surgery because of the risk of infection of the valve prosthesis as a result of the bacteremia from the abscess.

Mycotic Aneurysms

Mycotic aneurysms (MAs) are uncommon complications of IE. They result from septic embolization of vegetations to the arterial vasa vasorum or the intraluminal space, with subsequent spread of infection through the intima and outward through the vessel wall. Arterial branching points favor the impaction of emboli and are the most common sites of MA development. MAs due to IE occur most frequently in the intracranial arteries, followed by visceral arteries and arteries of the lower and upper extremities.^{123,124}

Intracranial MAs

Twenty to forty percent of patients with IE develop neurological complications.¹²⁵ Intracranial MAs (ICMAs) represent a relatively small but extremely dangerous subset of these. The overall mortality rate among IE patients with ICMAs is 60%. Among those without rupture, the mortality rate is 30%; this approaches 80% if rupture occurs.¹²⁶ The reported occurrence of ICMAs in 1.2% to 5% of cases^{127–131} is probably an underestimate because some ICMAs remain asymptomatic and resolve with antimicrobial therapy. Streptococci and *S aureus* account for $\approx 50\%$ and $\approx 10\%$ of cases, respectively,^{124,126,131} and are seen with increased frequency among IVDA patients with IE.¹³¹ The distal middle cerebral artery branches are most often involved, especially the bifurcations. ICMAs are multiple in 20% of cases¹³⁰; mortality rates are similar for multiple or single distal ICMAs. The mortality rate for patients with proximal ICMAs exceeds 50%.¹²⁶

The clinical presentation of patients with ICMAs is highly variable. Patients may develop severe localized headache, altered sensorium, or focal neurological deficits such as hemianopsia or cranial neuropathies; the neurological signs and symptoms may suggest a mass lesion or an embolic event.^{123,124,130} Some ICMAs leak slowly before rupture and produce mild meningeal irritation. Typically, the spinal fluid in these patients is sterile and contains erythrocytes, leukocytes, and elevated protein. In other patients, there are no clinically recognized premonitory findings before sudden subarachnoid or intraventricular hemorrhage.^{126,132}

In the absence of clinical signs or symptoms of ICMAs, routine screening with imaging studies is not warranted. Symptomatic cerebral emboli frequently but not invariably

precede the finding of an ICMA.^{133,134} Accordingly, imaging procedures to detect ICMA are indicated in IE patients with localized or severe headaches, "sterile" meningitis, or focal neurological signs.^{123,124,127,130} In patients suspected of having an ICMA, contrast-enhanced CT may provide useful initial information.¹³⁵ This technique has a 90% to 95% sensitivity for intracerebral bleed and may thus indirectly identify the location of the MA. Magnetic resonance angiography is a promising new technique for the detection of ICMA, although its sensitivity for aneurysms smaller than 5 mm is inferior to conventional 4-vessel cerebral angiography.¹³⁵ Until more experience is gained with other imaging modalities, conventional angiography remains the diagnostic imaging test of choice.^{129,135}

ICMA may heal with medical therapy: Bingham¹³⁶ reported that ICMA resolved between an initial and follow-up angiogram in 52% of patients treated with effective antibiotic therapy. A decrease in ICMA size was seen in an additional 29%. In 19% of patients, however, the ICMA increased in size by the time of the second angiogram, and a new ICMA was discovered in 10%. Whereas it is clear that ICMA treated with antibiotics alone will heal in many patients, in others, rupture may lead to significant morbidity or death. The risk of neurosurgical intervention is affected by patient age, underlying comorbid conditions, and the location of the ICMA. Currently, there are no data that precisely identify patients at risk for imminent rupture, and decisions concerning medical versus surgical therapy must be individualized. It is generally felt that a single ICMA distal to the first bifurcation of a major artery (eg, middle cerebral artery) should be monitored with frequent serial angiograms and excised promptly if the aneurysm enlarges or bleeds.¹²⁷ Multiple ICMA present a complex surgical problem and should be monitored closely with frequent serial angiograms and CT scans. If ≥ 1 aneurysm enlarges, prompt surgical excision should be considered. ICMA that occur proximal to the first bifurcation are less amenable to surgical excision. Such ICMA frequently arise from major vessels, and ligation may result in severe neurological deficits. Proximal aneurysms should be monitored with serial angiograms and CTs; in these lesions, if signs of enlargement or leakage develop, surgical intervention should be attempted. Occasionally, proximal ICMA stabilize and form a thrombus with antimicrobial therapy.¹³³

Some patients with IE require both cardiac valve replacement and ICMA ligation. Although data are limited in this situation, an approach that uses staged procedures, with the more severe problem dictating the procedure to be performed first, has been suggested.¹³⁷ A bioprosthetic valve, which does not require anticoagulant therapy, may be preferable to a mechanical valve in this circumstance.

Extracranial MAs

Intrathoracic or intra-abdominal MAs are often asymptomatic until leakage or rupture occurs. Presumably most extracranial MAs (ECMA) will rupture if not excised. The appearance of a tender, pulsatile mass in a patient with IE should suggest an ECMA. Hematemesis, hematuria, and jaundice suggest rupture of a hepatic artery MA; arterial hypertension and

hematuria suggest rupture of a renal MA; and massive bloody diarrhea suggests the rupture of an ECMA into the small or large bowel.

Proximal and distal ligation with excision of all infected material is ideal but generally not feasible. Moreover, the risk of reinfection and rupture of interposed vascular grafts is high. Revascularization is usually established via extra-anatomic routes through uninfected tissue planes. Autologous venous grafts have a lower risk of recurrent infection than synthetic materials.^{138,139} Long-term, suppressive, oral antimicrobial therapy may be desirable in patients at high risk of recurrence of infection, such as those with interposed vascular grafts in infected areas.

Despite improved diagnostic techniques and more aggressive surgical therapy, mortality among patients with IE and ECMA is high, which is attributable to suture-line infection with vessel or graft rupture. For most patients, however, surgical intervention represents the only hope for radical cure of the ECMA and survival.

Anticoagulation Issues

Questions arise as to whether anticoagulant therapy can be safely used during the treatment of IE. Anticoagulation per se is not a therapeutic regimen that should be used to treat IE. Most authorities feel that anticoagulation is contraindicated in native-valve endocarditis because of the risk of intracerebral hemorrhage.^{140,141} Patients with prosthetic-valve endocarditis who normally take maintenance anticoagulation, however, are usually maintained on anticoagulant therapy during treatment of IE, provided there is no evidence of cerebral events.⁵⁷

Conclusions

The incidence of IE continues to rise, with a yearly incidence of $\approx 15\,000$ to $20\,000$ new cases. Thus, IE now represents the fourth leading cause of life-threatening infectious disease syndromes (after urosepsis, pneumonia, and intra-abdominal sepsis). Although advances in antimicrobial therapy and the development of better diagnostic and surgical techniques have reduced the morbidity and mortality of IE, it remains a potentially life-threatening disease. The use of new clinical criteria, emphasizing echocardiography, will certainly guide the practitioner in correct diagnosis of this disease. Prompt recognition and management of the major complications of IE, such as heart failure, periannular extension of the infection, splenic abscess, and MAs, are also essential to successful patient outcome. Because of the rising incidence of IE, its significant morbidity and mortality rates, and its substantial prognostic and financial implications for the patient, it is vital to continue to fund research on endocarditis. This will in turn provide more information on the pathophysiology of the disease, as well as novel and better treatment and prophylactic strategies.

References

1. Wilson WR, Karchmer AW, Dajani AS, Taubert KA, Bayer A, Kaye D, Bisno AL, Ferrieri P, Shulman ST, Durack DT. Antibiotic treatment of adults with infective endocarditis due to streptococci, enterococci, staphylococci, and HACEK microorganisms: American Heart Association. *JAMA*. 1995;274:1706-1713.

2. Dajani AS, Taubert KA, Wilson W, Bolger AF, Bayer A, Ferrieri P, Gewitz MH, Shulman ST, Nouri S, Newburger JW, Hutto C, Pallasch TJ, Gage TW, Levison ME, Peter G, Zuccaro G Jr. Prevention of bacterial endocarditis: recommendations by the American Heart Association. *JAMA*. 1997;277:1794–1801.
3. Bayer AS. Infective endocarditis. *Clin Infect Dis*. 1993;17:313–320.
4. von Reyn CF, Levy BS, Arbeit RD, Friedland G, Crumpacker CS. Infective endocarditis: an analysis based on strict case definitions. *Ann Intern Med*. 1981;94:505–518.
5. Durack DT, Lukes AS, Bright DK. New criteria for diagnosis of infective endocarditis: utilization of specific echocardiographic findings: Duke Endocarditis Service. *Am J Med*. 1994;96:200–209.
6. Bayer AS, Lam K, Ginzton L, Norman DC, Chiu CY, Ward JI. *Staphylococcus aureus* bacteremia: clinical, serologic and echocardiographic findings in patients with and without endocarditis. *Arch Intern Med*. 1987;147:457–462.
7. Bayer AS, Ward JI, Ginzton LE, Shapiro SM. Evaluation of new clinical criteria for the diagnosis of infective endocarditis. *Am J Med*. 1994;96:211–219.
8. Hoen B, Selton-Suty C, Danchin N, Weber M, Willemot JP, Mathieu P, Floquet J, Canton P. Evaluation of the Duke criteria versus the Beth Israel criteria for the diagnosis of infective endocarditis. *Clin Infect Dis*. 1995;21:905–909.
9. Dodds GA, Sexton DJ, Durack DT, Bushore TM, Corey GR, Kisslo J. Negative predictive value of the Duke criteria for infective endocarditis. *Am J Cardiol*. 1996;77:403–407.
10. Arguello EA, Varini S, Romorini A, Elizari A, Clara L, Casabe H. Infective endocarditis in the Argentine Republic. Paper presented at: Third International Symposium on Modern Concepts in Endocarditis; July 13–15, 1995; Boston, Mass. Abstract 152A.
11. Kanavos K, Antoniadou A, Venetis C, Gezerlis P, Giamarellou H. Retrospective analysis of Duke's criteria in 60 cases of infective endocarditis. Paper presented at: Third International Symposium on Modern Concepts in Endocarditis; July 13–15, 1995; Boston, Mass. Abstract 138.
12. Del Pont JM, De Cicco LT, Vartalitis C, Ithuralde M, Gallo JP, Vargas F, Gianantonio CA, Quiros RE. Infective endocarditis in children: clinical analysis and evaluation of two diagnostic criteria. *Pediatr Infect Dis J*. 1995;14:1079–1086.
13. Stockheim JA, Chadwick EG, Kessler S, Amer M, Abdel-Haq N, Dajani AS, Shulman ST. Are the Duke criteria superior to Beth Israel criteria for the diagnosis of infective endocarditis in children? *Clin Infect Dis*. In press.
14. Nettles RE, McCarty DE, Corey GR, Li J, Sexton DJ. An evaluation of the Duke criteria in 25 pathologically confirmed cases of prosthetic valve infective endocarditis. *Clin Infect Dis*. 1997;25:1401–1403.
15. Heiro M, Nikoskelainen J, Hartiala JJ, Saraste MK, Kotilainen P. Diagnosis of infective endocarditis: sensitivity of the Duke vs von Reyn criteria. *Arch Intern Med*. 1998;158:18–24.
16. Gagliardi JP, Nettles RE, McCarthy DE, Sanders LL, Corey GR, Sexton DJ. Native valve infective endocarditis in elderly and younger adult patients: comparison of clinical features and outcomes using the Duke criteria and the Duke Endocarditis Database. *Clin Infect Dis*. 1998;26:1165–1168.
17. Hoen B, Beguinot I, Rabaud C, Jaussaud R, Selton-Suty C, May T, Canton P. The Duke criteria for diagnosing infective endocarditis are specific: analysis of 100 patients with acute fever or fever of unknown origin. *Clin Infect Dis*. 1996;23:298–302.
18. Sekeres MA, Abrutyn E, Berlin JA, Kaye D, Kinman JL, Korzeniowski OM, Levison ME, Feldman ME, Feldman RS, Strom BL. An assessment of the usefulness of the Duke criteria for diagnosing active infective endocarditis. *Clin Infect Dis*. 1997;24:1185–1190.
19. Fournier PE, Casalta JP, Habib G, Messina T, Raoult D. Modification of the diagnostic criteria proposed by the Duke Endocarditis Service to permit improved diagnosis of Q fever endocarditis. *Am J Med*. 1996;100:629–633.
20. Lamas CC, Eykyn SJ. Suggested modifications to the Duke criteria for the clinical diagnosis of native valve and prosthetic valve endocarditis: analysis of 118 pathologically proven cases. *Clin Infect Dis*. 1997;25:713–719.
21. Li J, Nettles RE, McCarty DE, Fowler V, Roe M, Ryan T, Sexton DJ, Corey GR. Clarifications of the Duke criteria for infective endocarditis. Paper presented at: Fourth International Symposium on Modern Concepts in Endocarditis and Cardiovascular Infections; May 22–24, 1997; Yverdon, Switzerland. Abstract 128.
22. Shively BK, Gurule FT, Roldan CA, Leggett JH, Schiller NB. Diagnostic value of transesophageal compared with transthoracic echocardiography in infective endocarditis. *J Am Coll Cardiol*. 1991;18:391–397.
23. Mugge A, Daniel WG, Frank G, Lichtlen PR. Echocardiography in infective endocarditis: reassessment of prognostic implications of vegetation size determined by the transthoracic and the transesophageal approach. *J Am Coll Cardiol*. 1989;14:631–638.
24. Shapiro SM, Young E, De Guzman S, Ward J, Chiu CY, Ginzton LE, Bayer AS. Transesophageal echocardiography in diagnosis of infective endocarditis. *Chest*. 1994;105:377–382.
25. Roy P, Tajik AJ, Guiliani ER, Schattenberg TT, Gau GT, Frye RL. Spectrum of echocardiographic findings in bacterial endocarditis. *Circulation*. 1976;53:474–482.
26. Daniel WG, Mugge A, Grote J, Hausmann D, Nikutta P, Laas J, Lichtlen PR, Martin RP. Comparison of transthoracic and transesophageal echocardiography for detection of abnormalities of prosthetic and bioprosthetic valves in the mitral and aortic positions. *Am J Cardiol*. 1993;71:210–215.
27. Daniel WG, Erbel R, Kasper W, Visser CA, Engberding R, Sutherland GR, Grube E, Hanrath P, Maisch B, Dennig K, Scharth M, Kremer P, Angermann C, Ilceto S, Curtius J, Mugge A. Safety of transesophageal echocardiography: a multicenter survey of 10,419 examinations. *Circulation*. 1991;83:817–821.
28. Rohmann S, Seifert T, Erbel R, Jakob H, Mohr-Kahaly S, Makowski T, Gorge G, Oelert H, Meyer J. Identification of abscess formation in native-valve infective endocarditis using transesophageal echocardiography: implications for surgical treatment. *Thorac Cardiovasc Surg*. 1991;39:273–280.
29. Karalis DG, Bansal RC, Hauck AJ, Ross JJ Jr, Applegate PM, Jutzy KR, Mintz GS, Chandrasekaran K. Transesophageal echocardiographic recognition of subaortic complications in aortic valve endocarditis: clinical and surgical implications. *Circulation*. 1992;86:353–362.
30. Daniel WG, Mugge A, Martin RP, Lindert O, Hausmann D, Nonnast-Daniel B, Laas J, Lichtlen PR. Improvement in the diagnosis of abscesses associated with endocarditis by transesophageal echocardiography. *N Engl J Med*. 1991;324:795–800.
31. Birmingham GD, Rahko PS, Ballantyne F III. Improved detection of infective endocarditis with transesophageal echocardiography. *Am Heart J*. 1992;123:774–781.
32. Nellessen U, Schnittger I, Appleton CP, Masuyama T, Bolger A, Fischell TA, Tye T, Popp RL. Transesophageal two-dimensional echocardiography and color Doppler flow velocity mapping in the evaluation of cardiac valve prostheses. *Circulation*. 1988;78:848–855.
33. Fowler VG Jr, Li J, Corey GR, Boley J, Marr KA, Gopal AK, Kong LK, Gottlieb G, Donovan CL, Sexton DJ, Ryan T. Role of echocardiography in evaluation of patients with *Staphylococcus aureus* bacteremia: experience in 103 patients. *J Am Coll Cardiol*. 1997;30:1072–1078.
34. Ali AS, Trivedi V, Lesch M. Culture-negative endocarditis: a historical review and 1990s update. *Prog Cardiovasc Dis*. 1994;37:149–160.
35. Vuille C, Nidorf M, Weyman AE, Picard MH. Natural history of vegetations during successful medical treatment of endocarditis. *Am Heart J*. 1994;128:1200–1209.
36. Rohmann S, Erbel R, Darius H, George G, Makowski T, Zotz R, Mohr-Kahaly S, Nixdorff U, Drexler M, Meyer J. Prediction of rapid versus prolonged healing of infective endocarditis by monitoring vegetation size. *J Am Soc Echocardiogr*. 1991;4:465–474.
37. von Reyn CF, Arbeit RD. Case definitions for infective endocarditis. *Am J Med*. 1994;96:220–222.
38. Washington JA. The microbiologic diagnosis of infective endocarditis. *J Antimicrob Chemother*. 1987;20(suppl A):29–36.
39. Werner AS, Cobbs CG, Kaye D, Hook EW. Studies on the bacteremia of bacterial endocarditis. *JAMA*. 1967;202:199–203.
40. Hoen B, Selton-Suty C, Lacassin F, Etienne J, Briancon S, Lepout C, Canton P. Infective endocarditis in patients with negative blood cultures: analysis of 88 cases from a one-year nationwide survey in France. *Clin Infect Dis*. 1995;20:501–506.
41. Tunkel AR, Kaye D. Endocarditis with negative blood cultures. *N Engl J Med*. 1992;326:1215–1217.
42. Cannady PB Jr, Sanford JP. Negative blood cultures in infective endocarditis: a review. *South Med J*. 1976;69:1420–1424.
43. Pazin GJ, Saul S, Thompson ME. Blood culture positivity: suppression by outpatient antibiotic therapy in patients with bacterial endocarditis. *Arch Intern Med*. 1982;142:263–268.
44. Spach DH, Kanter AS, Daniels NA, Nowowiejski DJ, Larson AM, Schmidt RA, Swaminathan B, Brenner DJ. *Bartonella (Rochalimaea)*

- species as a cause of apparent "culture-negative" endocarditis. *Clin Infect Dis*. 1995;20:1044-1047.
45. Larson AM, Dougherty MJ, Nowowiejski DJ, Welch DF, Matar GM, Swaminathan B, Coyle MB. Detection of *Bartonella (Rochalimaea) quintana* by routine acridine orange staining of broth blood cultures. *J Clin Microbiol*. 1994;32:1492-1496.
 46. Daly JS, Worthington MG, Brenner DJ, Moss CW, Hollis DG, Weyant RS, Steigerwalt AG, Weaver RE, Daneshivar MI, O'Connor SP. *Rochalimaea elizabethae* sp. nov. isolated from a patient with endocarditis. *J Clin Microbiol*. 1993;31:872-881.
 47. Spach DH, Kanter AS, Dougherty MJ, Larson AM, Coyle MB, Brenner DJ, Swaminathan B, Matar GM, Welch DF, Root RK, Stamm WE. *Bartonella (Rochalimaea) quintana* bacteremia in inner-city patients with chronic alcoholism. *N Engl J Med*. 1995;332:424-428.
 48. Drancourt M, Mainardi JL, Brouqui P, Vandenesch F, Carta A, Lehnert F, Etienne J, Goldstein F, Acar J, Raoult D. *Bartonella (Rochalimaea) quintana* endocarditis in three homeless men. *N Engl J Med*. 1995;332:419-423.
 49. Raoult D, Fournier PE, Drancourt M, Marrie TJ, Etienne J, Cosserrat J, Cacoub P, Poinignon Y, Leclercq P, Sefton AM. Diagnosis of 22 new cases of *Bartonella* endocarditis. *Ann Intern Med*. 1996;125:646-652.
 50. Tompkins LS, Roessler BJ, Redd SC, Markowitz LE, Cohen ML. Legionella prosthetic-valve endocarditis. *N Engl J Med*. 1988;318:530-535.
 51. Brouqui P, Dumler JS, Raoult D. Immunohistologic demonstration of *Coxiella burnetii* in the valves of patients with Q fever endocarditis. *Am J Med*. 1994;97:451-458.
 52. Shapiro DS, Kenney SC, Johnson M, Davis CH, Knight ST, Wyrick PB. Brief report: *Chlamydia psittaci* endocarditis diagnosed by blood culture. *N Engl J Med*. 1992;326:1192-1195.
 53. Stein A, Raoult D. Q fever endocarditis. *Eur Heart J*. 1995;16(suppl B):19-23.
 54. Hamed KA, Dormitzer PR, Su CK, Relman DA. *Haemophilus parainfluenzae* endocarditis: application of a molecular approach for identification of pathogenic bacterial species. *Clin Infect Dis*. 1994;19:677-683.
 55. Kostman JR, Mair M, DiNubile M. Detection of the etiologic agents of culture-negative endocarditis by polymerase chain reaction. In: *Abstracts of the 34th ICAAC*. Orlando, Fla: October 1994;98. Abstract D7.
 56. Goldenberger D, Kunzli A, Vogt P, Zbinden R, Altwegg M. Molecular diagnosis of bacterial endocarditis by broad-range PCR amplification and direct sequencing. *J Clin Microbiol*. 1997;35:2733-2739.
 57. Karchmer AW, Gibbons GW. Infections of prosthetic heart valves and vascular grafts. In: Bisno AL, Waldvogel FA, eds. *Infections Associated With Indwelling Medical Devices*. 2nd ed. Washington, DC: American Society for Microbiology; 1994:213-249.
 58. Baddour LM, Phillips TN, Bisno AL. Coagulase-negative staphylococcal endocarditis: occurrence in patients with mitral valve prolapse. *Arch Intern Med*. 1986;146:119-121.
 59. Caputo GM, Archer GL, Calderwood SB, DiNubile MJ, Karchmer AW. Native valve endocarditis due to coagulase-negative staphylococci: clinical and microbiologic features. *Am J Med*. 1987;83:619-625.
 60. Arber N, Militano A, Ben-Yehuda A, Krivoy N, Pinkhas J, Sidi Y. Native valve *Staphylococcus epidermidis* endocarditis: report of seven cases and review of the literature. *Am J Med*. 1991;90:758-763.
 61. Dehondt G, Leven M, Vandermerch C, Colaert J. Destructive endocarditis caused by *Staphylococcus lugdunensis*: case report and review of the literature. *Acta Clinica Belgica*. 1997;52:27-30.
 62. Vandenesch F, Etienne J, Reverdy ME, Eykyn SJ. Endocarditis due to *Staphylococcus lugdunensis*: report of 11 cases and review. *Clin Infect Dis*. 1993;17:871-876.
 63. Lessing MP, Crook DW, Bowler IC, Gribbin B. Native valve endocarditis caused by *Staphylococcus lugdunensis*. *QJM*. 1996;89:855-858.
 64. Etienne J, Brun Y, Fleurette J. *Staphylococcus lugdunensis* endocarditis. *J Clin Pathol*. 1989;42:892-893.
 65. Raoult D, Marrie T. Q fever. *Clin Infect Dis*. 1995;20:489-495.
 66. Levy PY, Drancourt M, Etienne J, Auvergnat JC, Beytout J, Sainy JM, Goldstein F, Raoult D. Comparison of different antibiotic regimens for therapy of 32 cases of Q fever endocarditis. *Antimicrob Agents Chemother*. 1991;35:533-537.
 67. Fernandez-Guerrero ML. Zoonotic endocarditis. *Infect Dis Clin North Am*. 1993;7:135-152.
 68. Cisneros JM, Pachon J, Cuello JA, Martinez A. *Brucella* endocarditis cured by medical treatment. *J Infect Dis*. 1989;160:907. Letter.
 69. Jacobs F, Abramowicz D, Vereerstraten P, Le Clerc JL, Zech F, Thys JP. *Brucella* endocarditis: the role of combined medical and surgical treatment. *Rev Infect Dis*. 1990;12:740-744.
 70. Moyer D, Edwards JE. Fungal endocarditis. In: Kaye D, ed. *Infective Endocarditis*. New York, NY: Raven Press; 1992.
 71. Weems JJ Jr. *Candida parapsilosis*: epidemiology, pathogenicity, clinical manifestations, and antimicrobial susceptibility. *Clin Infect Dis*. 1992;14:756-766.
 72. Melgar GR, Nasser RM, Gordon SM, Lytle BW, Keys TF, Longworth DL. Fungal prosthetic valve endocarditis: an 11-year experience in a tertiary care hospital. *Medicine*. 1997;76:94-103.
 73. Nguyen MH, Nguyen ML, Yu VL, McMahon D, Keys TF, Amidi M. *Candida* prosthetic valve endocarditis: prospective study of six cases and review of the literature. *Clin Infect Dis*. 1996;22:262-267.
 74. Lowry PW, Tompkins LS. Nosocomial legionellosis: a review of pulmonary and extrapulmonary syndromes. *Am J Infect Control*. 1993;21:21-27.
 75. Park D, Pugliese A, Cunha BA. *Legionella micdadei* prosthetic valve endocarditis. *Infection*. 1994;22:213-215.
 76. Reyes MP, Brown WJ, Lerner AM. Treatment of patients with *Pseudomonas* endocarditis with high dose aminoglycoside and carbenicillin therapy. *Medicine*. 1978;57:57-67.
 77. Wieland M, Lederman MM, Kline-King C, Keys TF, Lerner PI, Bass SN, Chmielewski R, Banks VD, Ellner JJ. Left-sided endocarditis due to *Pseudomonas aeruginosa*: a report of 10 cases and review of the literature. *Medicine*. 1986;65:180-189.
 78. Arbulu A, Holmes RJ, Asfaw I. Tricuspid valvectomy without replacement. *J Thorac Cardiovasc Surg*. 1991;102:917-922.
 79. Ingerman MJ, Pitsakis PG, Rosenberg AF, Levison ME. The importance of pharmacodynamics in determining the dosing interval in therapy for experimental *Pseudomonas* endocarditis in the rat. *J Infect Dis*. 1986;153:707-714.
 80. Pelletier LL Jr, Petersdorf RG. Infective endocarditis: a review of 125 cases from the University of Washington Hospitals, 1963-1972. *Medicine*. 1977;56:287-313.
 81. Mills J, Utley J, Abbott J. Heart failure in infective endocarditis: predisposing factors, course and treatment. *Chest*. 1974;66:151-157.
 82. Stinson EB. Surgical treatment of infective endocarditis. *Prog Cardiovasc Dis*. 1979;22:145-168.
 83. Wilson WR, Davidson GK, Giuliani ER, Washington JA II, Jaumin PM, Geraci JE. Cardiac valve replacement in congestive heart failure due to infective endocarditis. *Mayo Clin Proc*. 1979;54:223-226.
 84. Moon MR, Stinson EB, Miller DC. Surgical treatment of endocarditis. *Prog Cardiovasc Dis*. 1997;40:239-264.
 85. Karchmer AW, Stinson EB. The role of surgery in infective endocarditis. In: Remington JS, Schwartz MN, eds. *Current Clinical Topics in Infectious Diseases*. New York, NY: McGraw-Hill; 1980:124-157.
 86. Jung JY, Saab SB, Almond CH. The case for early surgical treatment of left-sided primary infective endocarditis: a collective review. *J Thorac Cardiovasc Surg*. 1975;70:509-518.
 87. Dreyfus G, Serraf A, Jebara VA, Deloche A, Chauvaud S, Couetil JP, Carpentier A. Valve repair in acute endocarditis. *Ann Thorac Surg*. 1990;49:706-711.
 88. Hendren WG, Morris AS, Rosenkranz ER, Lytle BW, Taylor PC, Stewart WJ, Loop FD, Cosgrove DM. Mitral valve repair for bacterial endocarditis. *J Thorac Cardiovasc Surg*. 1992;103:124-128.
 89. Lutas EM, Roberts RB, Devereux RB, Prieto LM. Relation between the presence of echocardiographic vegetations and the complication rate in infective endocarditis. *Am Heart J*. 1986;112:107-113.
 90. DeCastro S, Magni G, Beni S, Cartoni D, Fiorelli M, Venditti M, Schwartz SL, Fedele F, Pandian NG. Role of transthoracic and transesophageal echocardiography in predicting embolic events in patients with active infective endocarditis involving native cardiac valves. *Am J Cardiol*. 1997;80:1030-1034.
 91. Pruitt AA, Rubin RH, Karchmer AW, Duncan GW. Neurologic complications of bacterial endocarditis. *Medicine*. 1978;57:329-343.
 92. Garvey GJ, Neu HC. Infective endocarditis: an evolving disease: a review of endocarditis at the Columbia-Presbyterian Medical Center, 1968-1973. *Medicine*. 1978;57:105-127.
 93. Steckelberg JM, Murphy JG, Ballard D, Bailey K, Tajik AJ, Taliencio CP, Giuliani ER, Wilson WR. Emboli in infective endocarditis: the prognostic value of echocardiography. *Ann Intern Med*. 1991;114:635-640.
 94. Sanfilippo AJ, Picard MH, Newell JB, Rosas E, Davidoff R, Thomas JD, Weyman AE. Echocardiographic assessment of patients with infectious

- endocarditis: prediction of risk for complications. *J Am Coll Cardiol.* 1991;18:1191-1199.
95. Erbel R, Rohmann S, Drexler M, Mohr-Kahaly S, Gerharz CD, Iverson S, Oelert H, Meyer J. Improved diagnostic value of echocardiography in patients with infective endocarditis by transoesophageal approach: a prospective study. *Eur Heart J.* 1988;9:43-53.
 96. Rohmann S, Erbel R, Gorge G, Makowski T, Mohr-Kahaly S, Nixdorff U, Drexler M, Meyer J. Clinical relevance of vegetation localization by transoesophageal echocardiography in infective endocarditis. *Eur Heart J.* 1992;13:446-452.
 97. Durack DT. Nine controversies in the management of endocarditis. In: Petersdorf RG, ed. *Update V: Harrison's Principles of Internal Medicine.* New York, NY: McGraw-Hill; 1984:35.
 98. Alsip SG, Blackstone EH, Kirklint JW, Cobbs CG. Indications for cardiac surgery in patients with active infective endocarditis. *Am J Med.* 1985;78(suppl 6B):138-148.
 99. Croft CH, Woodward W, Elliott A, Commerford PJ, Barnard CN, Beck W. Analysis of surgical versus medical therapy in active complicated native valve infective endocarditis. *Am J Cardiol.* 1983;51:1650-1655.
 100. Omari B, Shapiro S, Ginzton L, Robertson JM, Ward J, Nelson RJ, Bayer AS. Predictive risk factors for periannular extension of native valve endocarditis: clinical and echocardiographic analyses. *Chest.* 1989;96:1273-1279.
 101. Middlemost S, Wisenbaugh T, Meyerowitz C, Teeger S, Essop R, Skoularigis J, Cronje S, Sareli P. A case for early surgery in native left-sided endocarditis complicated by heart failure: results in 203 patients. *J Am Coll Cardiol.* 1991;18:663-667.
 102. Blumberg EA, Karalis DA, Chandrasekaran K, Wahl JM, Vilaro J, Covalesky VA, Mintz GS. Endocarditis-associated paravalvular abscesses: do clinical parameters predict the presence of abscess? *Chest.* 1995;107:898-903.
 103. Becher H, Hanrath P, Bleifeld W, Bleese N. Correlation of echocardiographic and surgical findings in acute bacterial endocarditis. *Eur Heart J.* 1984;5(suppl C):67-70.
 104. Arnett EN, Roberts WC. Prosthetic valve endocarditis: clinicopathologic analysis of 22 necropsy patients with comparison of observations in 74 necropsy patients with active infective endocarditis involving natural left-sided cardiac valves. *Am J Cardiol.* 1976;38:281-292.
 105. Fericola DJ, Roberts WC. Frequency of ring abscess and cuspal infection in active infective endocarditis involving bioprosthetic valves. *Am J Cardiol.* 1993;72:314-323.
 106. Carpenter JL. Perivalvular extension of infection in patients with infectious endocarditis. *Rev Infect Dis.* 1991;13:127-138.
 107. Daniel WG, Schroder E, Nonnast-Daniel B, Lichtlen PR. Conventional and transoesophageal echocardiography in the diagnosis of infective endocarditis. *Eur Heart J.* 1984;8(suppl J):287-292.
 108. Leung DY, Cranney GB, Hopkins AP, Walsh WF. Role of transoesophageal echocardiography in the diagnosis and management of aortic root abscesses. *Br Heart J.* 1994;72:175-181.
 109. Kunis RL, Sherrid MV, McCabe JB, Grieco MH, Dwyer EM Jr. Successful medical therapy of mitral annular abscess complicating infective endocarditis. *J Am Coll Cardiol.* 1986;7:953-955.
 110. Vlessis AA, Hovaguimian H, Jagers J, Ahmad A, Starr A. Infective endocarditis: ten-year review of medical and surgical therapy. *Ann Thorac Surg.* 1996;61:1217-1222.
 111. Mullany CJ, Chua YL, Schaff HV, Steckelberg JM, Ilstrup DM, Orszulak TA, Danielson GK, Puga FJ. Early and late survival after surgical treatment of culture-positive active endocarditis. *Mayo Clin Proc.* 1995;70:517-525.
 112. Glazier JJ, Verwilghen J, Donaldson RM, Ross DN. Treatment of complicated prosthetic aortic valve endocarditis with annular abscess formation by homograft aortic root replacement. *J Am Coll Cardiol.* 1991;17:1177-1182.
 113. Ross D. Allograft root replacement for prosthetic endocarditis. *J Card Surg.* 1990;5:68-72.
 114. McGiffin DC, Galbraith AJ, McLachlan GJ, Stower RE, Wong ML, Stafford EG, Gardner MA, Pohlner PG, O'Brien MF. Aortic valve infection: risk factors for death and recurrent endocarditis after aortic valve replacement. *J Thorac Cardiovasc Surg.* 1992;104:511-520.
 115. Johnson JD, Raff MJ, Barnwell PA, Chun CH. Splenic abscess complicating infectious endocarditis. *Arch Intern Med.* 1983;143:906-912.
 116. Mansur AJ, Grinberg M, da Luz PL, Bellotti G. The complications of infective endocarditis: a reappraisal in the 1980s. *Arch Intern Med.* 1992;152:2428-2432.
 117. Ting W, Silverman NA, Arzouman DA, Levitsky S. Splenic septic emboli in endocarditis. *Circulation.* 1990;82(suppl IV):IV-105-IV-109.
 118. Chun CH, Raff MJ, Contreas L, Varghese R, Waterman N, Daffner R, Melo JC. Splenic abscess. *Medicine.* 1980;59:50-65.
 119. Robinson SL, Saxe JM, Lucas CE, Arbulu A, Ledgerwood AM, Lucas WF. Splenic abscess associated with endocarditis. *Surgery.* 1992;112:781-786.
 120. Magilligan DJ. Splenic abscess. In: Magilligan DJ, Quinn EL, eds. *Endocarditis: Medical and Surgical Management.* New York, NY: Marcel Dekker; 1984:197-204.
 121. Lerner RM, Spataro RF. Splenic abscess: percutaneous drainage. *Radiology.* 1984;153:643-645.
 122. Chou YH, Hsu CC, Tiu CM, Chang T. Splenic abscess: sonographic diagnosis and percutaneous drainage or aspiration. *Gastrointest Radiol.* 1992;17:262-266.
 123. Stengel A, Wolferth CC. Mycotic (bacterial) aneurysms of intravascular origin. *Arch Intern Med.* 1923;31:527-554.
 124. Wilson WR, Lie JT, Houser OW, Piepgras DG, Geraci JE. The management of patients with mycotic aneurysm. *Curr Clin Top Infect Dis.* 1981;2:151-183.
 125. Francioli P. Central nervous system complications of infective endocarditis. In: Scheld WM, Whiteley RJ, Durack DT, eds. *Infections of the Central Nervous System.* New York, NY: Raven Press; 1991:515-559.
 126. Bohmfalk GL, Story JL, Wissing JP, Brown WE Jr. Bacterial intracranial aneurysm. *J Neurosurg.* 1978;48:369-382.
 127. Wilson WR, Giuliani ER, Danielson GK, Geraci JE. Management of complications of infective endocarditis. *Mayo Clin Proc.* 1982;57:162-170.
 128. Houspian EM, Pool JL. A systematic analysis of intracranial aneurysms from the autopsy file of Presbyterian Hospital, 1914-1956. *J Neuropathol Exp Neurol.* 1958;17:409-423.
 129. Camarata PJ, Latchaw RE, Rufenacht DA, Heros RC. Intracranial aneurysms. *Invest Radiol.* 1993;28:373-382.
 130. Lerner P. Neurologic complications of infective endocarditis. *Med Clin North Am.* 1985;69:385-398.
 131. Clare CE, Barrow DL. Infectious intracranial aneurysms. *Neurosurg Clin N Am.* 1992;3:551-566.
 132. Roach MR, Drake CG. Ruptured cerebral aneurysms caused by microorganisms. *N Engl J Med.* 1965;273:240-244.
 133. Cantu RC, LeMay M, Wilkinson HA. The importance of repeated angiography in the treatment of mycotic-embolic intracranial aneurysms. *J Neurosurg.* 1966;25:189-193.
 134. Moskowitz MA, Rosenbaum AE, Tyler HR. Angiographically monitored resolution of cerebral mycotic aneurysms. *Neurology.* 1974;24:1103-1108.
 135. Huston J III, Nichols DA, Luetmer PH, Goodwin JT, Meyer FB, Wiebers DO, Weaver AL. Blinded prospective evaluation of sensitivity of MR angiography to known intracranial aneurysms: importance of aneurysm size. *Am J Neuroradiol.* 1994;15:1607-1614.
 136. Bingham WF. Treatment of mycotic intracranial aneurysms. *J Neurosurg.* 1977;46:428-437.
 137. Jara FM, Lewis JF Jr, Magilligan DJ Jr. Operative experience with infective endocarditis and intracerebral mycotic aneurysm. *J Thorac Cardiovasc Surg.* 1980;80:28-30.
 138. Mundth ED, Darling RC, Alvarado RH, Buckley MJ, Linton RR, Austen WG. Surgical management of mycotic aneurysms and the complications of infection in vascular reconstructive surgery. *Am J Surg.* 1969;117:460-470.
 139. Yellin AE. Ruptured mycotic aneurysm: a complication of parenteral drug abuse. *Arch Surg.* 1977;112:981-986.
 140. Hart RG, Kagan-Hallet K, Joerns SE. Mechanisms of intracranial hemorrhage in infective endocarditis. *Stroke.* 1987;18:1048-1056.
 141. Kanter MC, Hart RG. Neurologic complications of infective endocarditis. *Neurology.* 1991;41:1015-1020.

KEY WORDS: **AHA Scientific Statement** ■ endocarditis ■ diagnosis ■ echocardiography